

## Please read this bit first

The HPCSA and the Med Tech Society have confirmed that this clinical case study, plus your routine review of your EQA reports from Thistle QA, should be documented as a "Journal Club" activity. This means that you must record those attending for CEU purposes. Thistle will **not** issue a certificate to cover these activities, nor send out "correct" answers to the CEU questions at the end of this case study.

The Thistle QA CEU No is: **MT00025**.

Each attendee should claim **THREE** CEU points for completing this Quality Control Journal Club exercise, and retain a copy of the relevant Thistle QA Participation Certificate as proof of registration on a Thistle QA EQA.

**June 2007**

## Liver Function

### Case presentation

A man aged 35 years, with a five-year history of ankylosing spondylitis, presented with a ten-day history of anorexia, malaise, loss of weight, and mild diffuse right upper abdominal pain. Five days previously he noticed that his urine was dark; and the days before admission his wife noticed that he was becoming increasingly yellow. In the past he had been treated with indomethacin for his spinal condition, but this had recently been changed to phenylbutazone. He had no contact with infectious hepatitis patients, had no recent intravenous therapy, and was a non-drinker.

On examination he was jaundiced and had a tender liver which extended 3cm below the costal margin. The values for the routine liver function tests are shown below.

### Plasma

TPro	71	g/L	(62 – 82)
Alb	39	g/L	(30 – 50)
ALP	585	U/L	(30 – 120)
ALT	536	U/L	(<35)
Bili	72	$\mu\text{mol/L}$	(<20)
GGT	125	U/L	(<45)

### Urine

Bili	+ve
Urobilinogen	+ve

### Differential diagnosis

The causes of hyperbilirubinaemia are listed in Table 12.1. In this case the possibilities include: *infectious hepatitis, drug-induced liver disease, obstructive biliary disease*

---

**Table 12.1.** Causes of hyperbilirubinaemia

**Increased production**

*Haemolytic anaemia*

**Decreased excretion**

*Congenital disorders*

Gilbert's disease, Crigler-Najjar syndrome, Dubin-Johnson syndrome

*Predominant hepatocellular disease*

Hepatitis: acute, chronic; Anoxie: cardiac failure, shock;  
Drugs/toxins

*Predominant cholestasis*

Obstruction: intrahepatic, extrahepatic; Space-occupying lesions;  
Drugs; Cirrhosis

*Hepatocellular and cholestasis*

Cholestatic hepatitis; Chronic active hepatitis; Cirrhosis;  
Prolonged biliary obstruction

---

**Case discussion**

In the above patient both the plasma ALP and ALT are greatly increased (ALP>3-fold, ALT>10-fold, the upper limit of normal), indicating that there is hepatocellular damage as well as significant cholestasis (**Figure 12.1**). Thus, the possibilities include:

- acute hepatitis, cholestatic variety
- chronic active hepatitis
- prolonged biliary obstruction
- decompensated liver cirrhosis

The last three disorders listed can be excluded on the following grounds:

**Chronic active hepatitis:** This disorder is defined as hepatitis which has been present for more than three months (Whitcomb F. F., 1979); the present patient's illness is acute. However, chronic acute hepatitis is still a likely diagnosis and can only be definitely excluded based on the clinical progress of the disease and a liver biopsy.

**Prolonged biliary obstruction:** The short history of liver disease in this patient excludes this diagnosis; however, primary biliary cirrhosis is a possibility.

**Decompensated liver cirrhosis:** The patient had no previous history of liver disease, and his normal plasma albumin level does not suggest any severe degree of liver dysfunction. However, neither of these two factors exclude the diagnosis and again a biopsy would be needed for confirmation.

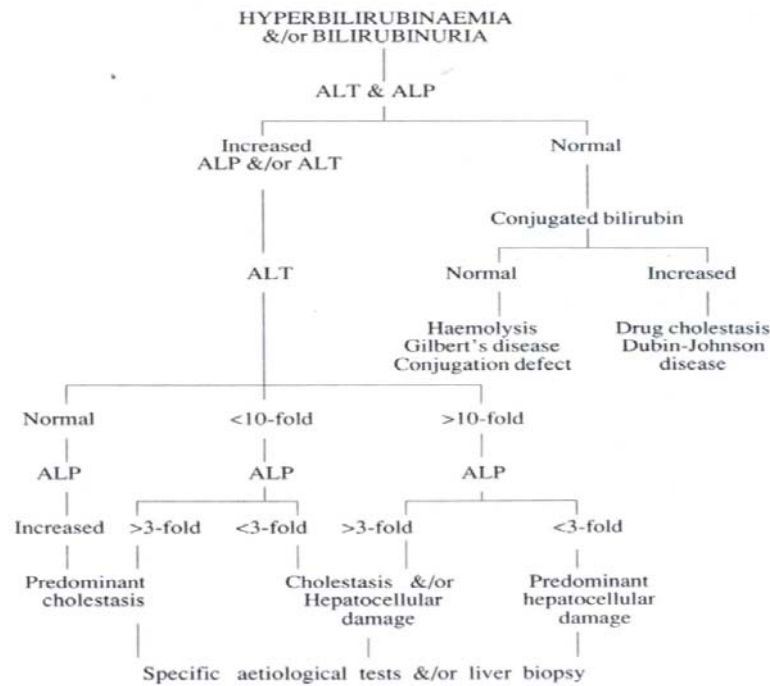


Figure 12.1. Suggested scheme for the investigation of the jaundiced patient

### Final diagnosis:

The only really positive finding in this patient, from an aetiological consideration, is his exposure to phenylbutazone. This drug is known to cause liver disease of both the hepatocellular and cholestatic variety (Zimmerman H. J., 1975). The drug was withdrawn and the patient's condition resolved over the following two weeks although his plasma ALP level remained elevated for another two weeks. A liver biopsy was not performed.

### CPD Questions:

1. Investigate the three diseases/symptoms mentioned under 'Congenital disorders' in Table 12.1.
2. What is meant by the term 'cholestasis'?